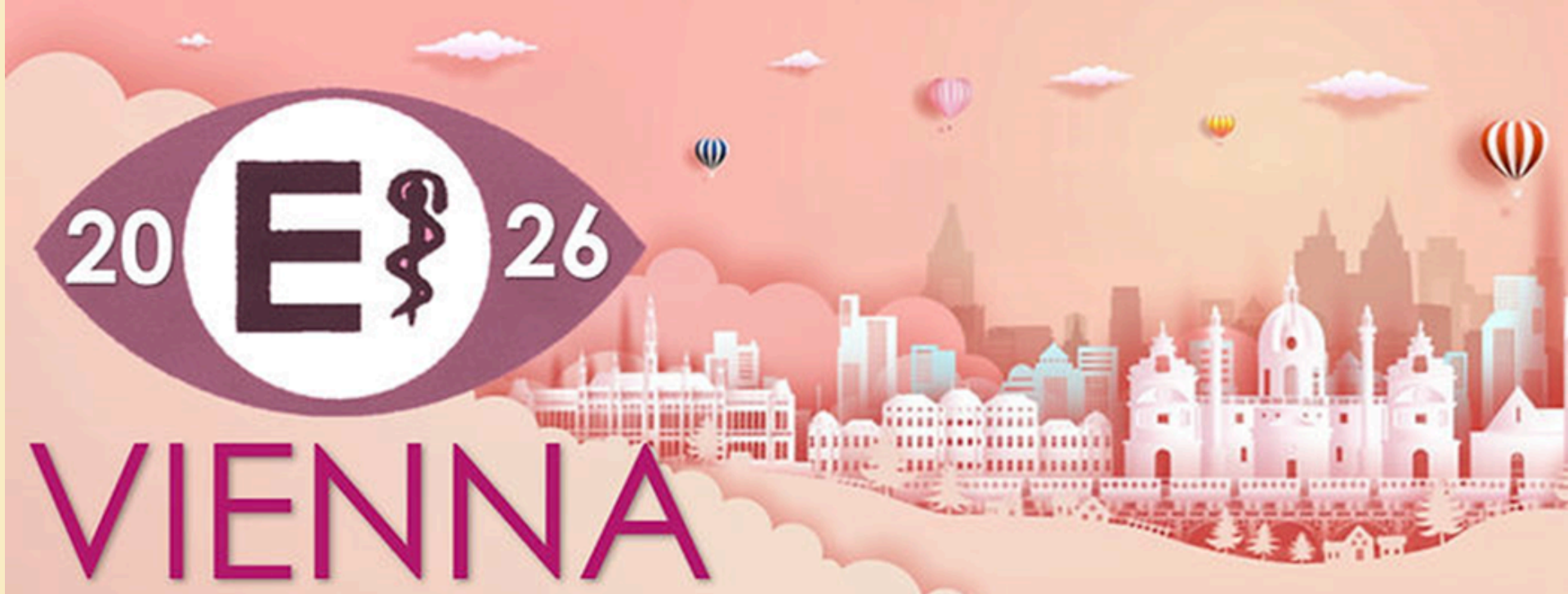

# EFFECTS OF MULTIFOCAL CONTACT LENSES ON ANTERIOR AND POSTERIOR SEGMENT OCT PARAMETERS

BAŞAK TURUN BOZKURT, M.D.<sup>1</sup>  
 ATILIM ARMAĞAN DEMİRTAŞ, M.D., ASSOC. PROF., FEBO<sup>12</sup>  
 BERNA YUCE, M.D., ASSOC. PROF., FEBO<sup>12</sup>  
 TUNCAY KUSBECI, M.D., PROF.<sup>12</sup>



<sup>1</sup>DEPARTMENT OF OPHTHALMOLOGY, IZMIR CITY HOSPITAL, IZMIR, TÜRKIYE  
<sup>2</sup> DEPARTMENT OF OPHTHALMOLOGY, IZMIR FACULTY OF MEDICINE, UNIVERSITY OF HEALTH SCIENCES TÜRKIYE, IZMIR, TÜRKIYE



## PURPOSE

THIS STUDY AIMED TO EVALUATE THE INFLUENCE OF MULTIFOCAL CONTACT LENSES (MFCLS) ON STRUCTURAL OPTICAL COHERENCE TOMOGRAPHY (OCT) PARAMETERS, INCLUDING CENTRAL CORNEAL THICKNESS (CCT), GANGLION CELL-INNER PLEXIFORM LAYER (GCIPL) THICKNESS, AND PERIPAPILLARY RETINAL NERVE FIBER LAYER (RNFL) THICKNESS. IN ADDITION, WE ASSESSED THEIR EFFECT ON SCAN ACQUISITION QUALITY, AS MEASURED BY THE OCT QUALITY INDEX (QI).

## KEYWORDS

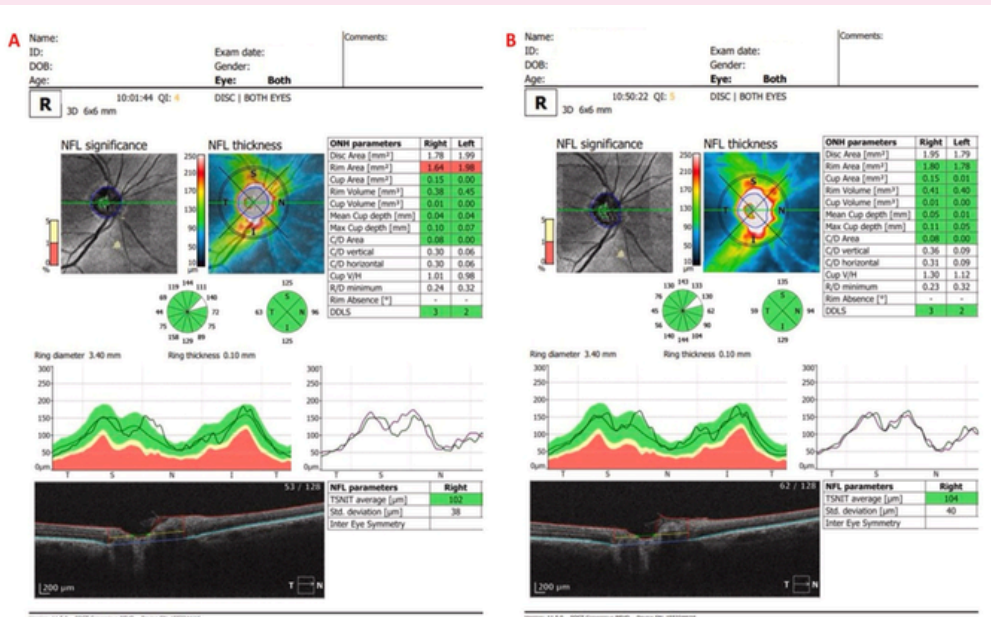
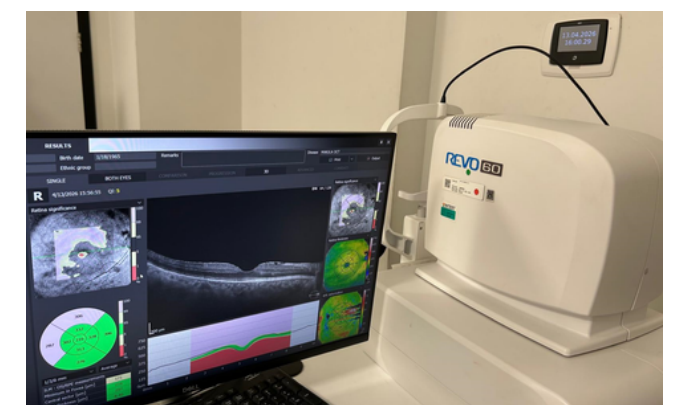
- Central corneal thickness
- Ganglion cell-inner plexiform layer
- Multifocal contact lenses
- Optical coherence tomography
- Retinal nerve fiber layer
- Quality index

## METHODOLOGY

A retrospective cross-sectional study was performed on 80 eyes of 40 female presbyopic participants (mean age 52.4 ± 6.1 years). All subjects were fitted with Acuvue Oasys Multifocal lenses (Johnson & Johnson Vision). OCT imaging was performed for the anterior segment, ganglion, and disc analyses both with and without MFCLs. Parameters assessed included CCT, average and minimum GCIPL thickness, average RNFL thickness, and scan QI. Only scans with QI ≥ 4 were included. Correlation analyses were performed between OCT parameters and clinical parameters (age, spherical equivalent, K1, K2, and corneal radius), and MFCL variables (spherical power and addition levels)

## RESULTS

Linear mixed model analysis revealed significant differences in several OCT parameters between lens-off and lens-on conditions. CCT slightly increased with MFCL wear (adjusted means of difference = +1.9 μm, p < 0.001), while anterior scan quality remained stable. In contrast, posterior segment scan quality decreased significantly in both ganglion (p = 0.003) and disc (p = 0.002) modules, accompanied by a reduction in average RNFL thickness (adjusted means of difference = -3.19 μm, p < 0.001). Correlation analyses showed that both spherical equivalent and MFCL spherical power were significantly associated with GCIPL thickness, suggesting a subtle optical influence of refractive status and lens power on retinal measurements. Addition levels showed no significant correlations with any OCT-derived parameter.



**Table 2**  
 Linear mixed model analysis of changes in OCT measurements with and without MFCLs.

	mean ± SD		adjusted means of difference (n = 80)	p
	without MFCLs (n = 80)	with MFCLs (n = 80)		
<b>Anterior segment analysis</b>				
QI	7.03 ± 2.11	6.97 ± 1.87	-0.05	0.893
Central corneal thickness (μm)	533.8 ± 30.43	535.7 ± 29.42	1.9	<0.001
<b>Ganglion analysis</b>				
QI	6.08 ± 2.15	4.83 ± 2.3	-1.25	0.003
Average GCIPL thickness (μm)	88.72 ± 7.53	89.47 ± 5.51	0.75	0.378
Minimum GCIPL thickness (μm)	40.69 ± 12.45	43.38 ± 10.81	2.69	0.107
<b>Disc analysis</b>				
QI	5.92 ± 2.14	4.67 ± 2.06	-1.26	0.002
Average RNFL thickness (μm)	99.51 ± 9.26	96.32 ± 9.93	-3.19	<0.001

OCT: optical coherence tomography, MFCL: multifocal contact lens, SD: standard deviation, QI: quality index, GCIPL: ganglion cell-inner plexiform layer, RNFL: retinal nerve fiber layer.  
 p < 0.05 marked bold.

## CONCLUSION

:MFCL wear was associated with reduced OCT image quality in posterior segment imaging and with thinner RNFL measurements, while anterior segment quality and GCIPL parameters remained stable. Correlation analyses revealed that refractive status and lens spherical power subtly influenced GCIPL thickness. Therefore, OCT examinations in presbyopic patients should be interpreted with caution, and baseline scans without lens wear may be preferable, particularly in glaucoma screening.



## REFERENCES

- D. Madrid-Costa, L. Isla-Paradelo, S. García-L'azaro, C. Albarr' an-Diego, J. RuizAlcocer, Effect of multizone refractive multifocal contact lenses on the Cirrus HD OCT retinal measurements, Clin. Exp. Optom. 96 (1) (2013) 53-57, <https://doi.org/10.1111/j.1444-0938.2012.00758.x>.
- D.J. Youm, J.M. Kim, K.H. Park, C.Y. Choi, The effect of soft contact lenses during the measurement of retinal nerve fiber layer thickness using optical coherence tomography, Curr. Eye Res. 34 (1) (2009) 78-83, <https://doi.org/10.1080/02713680802579188>.
- D.L. Budenz, R.T. Chang, X. Huang, R.W. Knighton, J.M. Tielsch, Reproducibility of retinal nerve fiber thickness measurements using the stratus OCT in normal and glaucomatous eyes, Invest. Ophthalmol. Vis. Sci. 46 (7) (2005) 2440-2443, <https://doi.org/10.1167/iops.04-1174>.